

**Mr Vaughan Tanner**  
*BSc MBBS FRCOphth*  
Consultant Ophthalmic Surgeon

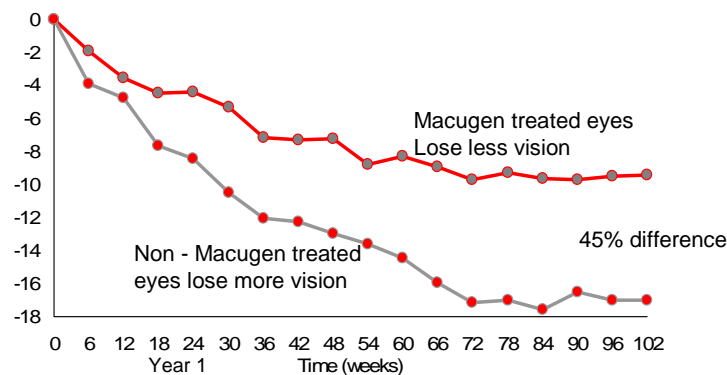
**Telephone:** 01189 553457  
01753 743418

<http://www.tanner-eyes.co.uk>

## **Patient Information:** **Anti VEGF agents – Lucentis, Macugen and Avastin**

The last year has seen significant advantages in the management of wet age related macular degeneration with the introduction of intravitreal, vascular endothelial growth factor antibodies (anti VEGF). For the last five years photodynamic therapy (PDT) has offered some hope to patients with wet ARMD but this has mainly resulted in a lower rate of visual loss in most cases rather than significant improvement even when combined with Triamcinolone steroid injections. In April 2006 the anti VEGF agent known as Macugen became fully licensed and available for the treatment of all forms of wet age related macular degeneration in the UK via monthly injection. This agent specifically binds the VEGF165 isomer. Macugen has the advantage of avoiding the 2 – 3% incidence of visual loss which occurs with PDT, the ability to treat all forms of wet ARMD and avoids the side effects of steroid use. However, it is expensive and in terms of visual outcome tends to result in stabilisation rather than improvement in vision.

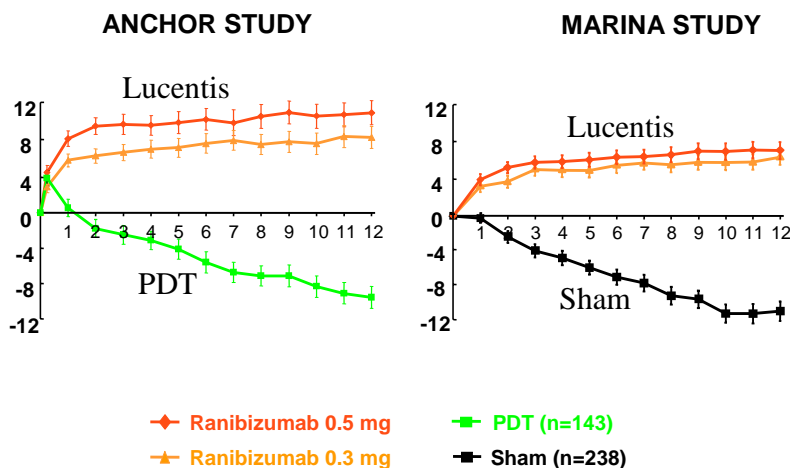
**Macugen Treatment**  
Average change in vision over 2 years



Another anti VEGF agent Lucentis (Ranibizumab) is a more exciting opportunity as up to 40% of patients with any form of wet ARMD have been shown to increase vision on treatment with the rest stabilising vision. Lucentis is a humanised anti-VEGF antibody fragment that binds all VEGF isomers. Fortunately Lucentis was licensed for use in the UK in early 2007 and is now funded by all the major insurance companies. Initial experience with Lucentis has been extremely encouraging over the last twelve months with some patients managing restoration of reading vision in what has for so long been an essentially untreatable disease.

## Lucentis Treatment

**Lucentis treated patients gained vision over one year on average compared to those having PDT laser or no treatment**



Lucentis is given as a series of 3, monthly injections with further injections depending on individual patient response. Some patients only need 3 injections but in others, the challenge now remains to decrease the number of injections required so that patients do not have to continue with monthly injections over a prolonged period. Results of further trials are awaited and it is hoped that a significant number of patients will stabilise after three or four treatments rather than requiring two years of monthly injections as described in the initial trials.

You may be aware of intravitreal Avastin (Bevacizumab). This anti VEGF agent was initially designed for use in colorectal cancer and is the parent molecule of Lucentis. Prior to Lucentis being licensed in the United States a large number of patients were injected with Avastin to good effect and no obvious side effects. However, it is the the Lucentis molecule which has been specifically designed for use in the eye and at the moment there is little prospect of Avastin being formally licensed with some doubt over its safety, given the lack of

formal development. Nevertheless it is currently so much cheaper that it may be considered as an alternative for those patients who can not afford lucentis. See Summary on [Royal College of Ophthalmologists website](#).

The private health insurance companies are beginning to recognise anti VEGF therapy as an acceptable treatment and the campaign is beginning to ensure these agents are available on the NHS. I hope you find the above, brief summary of interest. If you need any further information do please contact Jacquie my personal assistant on 01189 553457 or [secretary@tanner-eyes.co.uk](mailto:secretary@tanner-eyes.co.uk)

## **The Procedure Itself**

All intravitreal injections are carried out under sterile conditions to minimise the chance of any infection and will be done in an operating theatre environment. The injection only takes a few minutes, will be given under a local anaesthetic and is not painful. Following application of antibiotic drops and anaesthetic drops a small volume (usually 0.05ml) of the drug is injected via a very fine needle through the wall of the eye. Patients occasionally notice some floaters in the eye as the drug is injected. The procedure is carried out as a day case and you can usually leave hospital an hour after receiving the injection.

## **What Are the Risks Involved?**

1. Endophthalmitis (infection in the eye) – there is approximately 0.1% risk (one in a thousand) of developing serious infection in the eye following an injection of any kind. For this reason every precaution is taken to avoid any infective risk, with multiple applications of antibiotics before and after the procedure and scrupulous attention to sterile technique. I have never actually had this complication and indeed carry out very much more complex procedures on a routine basis, again without any infective problems. It does, however, remain potentially the most serious complication associated with any injection into the eye.
2. High pressure in the eye – this is usually transient and related to the small additional volume of fluid going into the eye
3. Bleeding and retinal detachment are unusual complications that have been reported in the literature.
4. There is a theoretical systemic risk from anti VEGF agents that they may increase the risk of thromboembolic events such as stroke. The trials are a

little conflicting in this and of course in this age group there does tend to be a background level of other medical problems anyway. Again we await further trials.

---

**Disclaimer**

*The information provided in this document is intended as a useful aid to general practitioners, optometrists and patients. It is impossible to diagnose and treat patients adequately without a thorough eye examination by a qualified ophthalmologist, optometrist or your general practitioner. Hopefully the information will be of use prior to and following a consultation which it supplements and does not replace.*

**Copyright**

*All images and graphics used in this document are subject to copyright law. Mr Tanner is particularly grateful to Mr JJ Kanski and for allowing reproduction of several of his clinical photos on this document.*