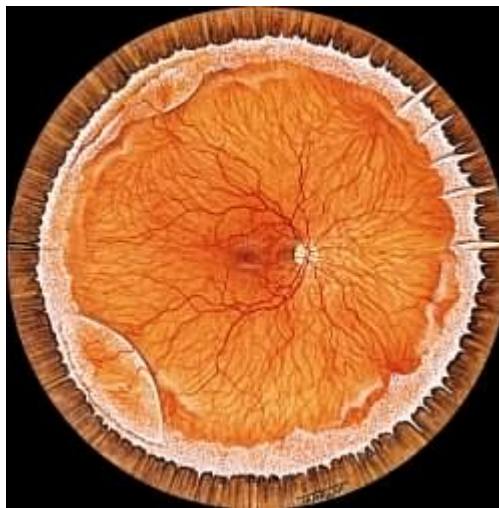


Mr Vaughan Tanner
BSc MBBS FRCOphth
Consultant Ophthalmic Surgeon

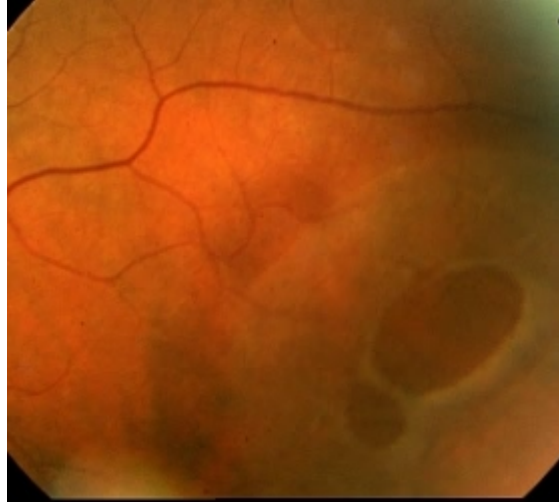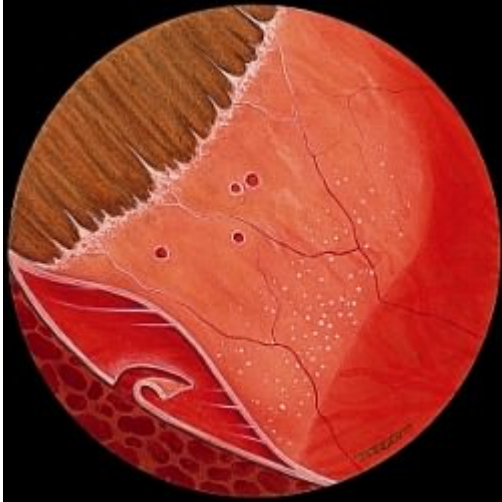Telephone: 01189 553457
01753 743418

<http://www.tanner-eyes.co.uk>

Patient Information: Retinoschisis



Retinoschisis is the term given to a fairly common condition in which the peripheral retina degenerates to form a cyst like cavity within the retinal layers. In the vast majority of cases the cysts do not progress to a true retinal detachment or involve central vision in any way. In the few cases where progression does occur to retinal detachment, surgery can be very challenging. Routine prophylactic laser or cryotherapy treatment is occasionally of benefit. The condition frequently affects the inferior retina in both eyes and is not thought to be hereditary. It is usually picked up as an asymptomatic finding during a visit to the opticians and is thought to be commoner in long-sighted people.



The above pictures show a schematic and clinical photo of retinoschisis, which has developed holes in both the inner and outer retinal layers to form a retinal detachment. Even in these cases progression to visual loss is unusual.

Disclaimer

The information provided in this document is intended as a useful aid to general practitioners, optometrists and patients. It is impossible to diagnose and treat patients adequately without a thorough eye examination by a qualified ophthalmologist, optometrist or your general practitioner. Hopefully the information will be of use prior to and following a consultation which it supplements and does not replace.

Copyright

All images and graphics used in this document are subject to copyright law. Mr Tanner is particularly grateful to Mr JJ Kanski for allowing reproduction of several of his clinical photos on this document.