

Mr Vaughan Tanner
BSc MBBS FRCOphth
Consultant Ophthalmic Surgeon

Telephone: 01189 553457
01753 743418

<http://www.tanner-eyes.co.uk>

Patient Information:

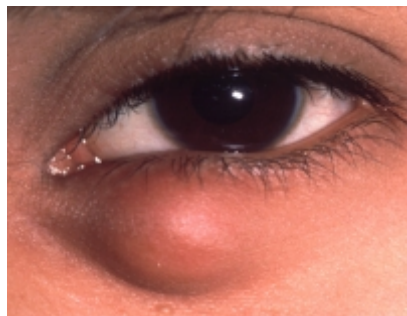Chalazion

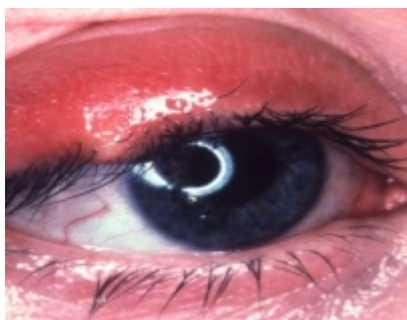
This is a common condition and is caused by a blockage in one of the small glands in the eyelid. A small lump develops as the normal contents cannot escape. Although it is unsightly, it is easy to treat and should not cause you any major problems with your vision.

As a first step in treatment, you may be prescribed antibiotics to reduce the inflammation in the eyelid. Heat treatment with hot compresses can also help and may actually release the contents of the cyst which means that further intervention is not needed.

If it has not resolved on this treatment, it can be removed with a minor procedure.

Photographs of typical cases of eyelid chalazion, affecting lower and upper lids





Treatment

Your eyelid will be numbed by an anaesthetic injection to the area. This may sting a little initially, but the lid will soon become frozen.

The cyst is removed from the inside of the eyelid - no stitches are necessary, and no scar will be visible. Antibiotic ointment will then be applied, followed by an eye pad.

The pad is usually left in place overnight. You may be given ointment to use in the eye for 3-4 subsequent days.

Often the lid is bruised following the procedure - do not worry, this is normal and will resolve within 2 weeks.

Some people are prone to getting these lumps again. You can help prevent them from re-occurring by using hot compresses on the lids and massaging them in the morning (see information on blepharitis).

Disclaimer

The information provided in this document is intended as a useful aid to general practitioners, optometrists and patients. It is impossible to diagnose and treat patients adequately without a thorough eye examination by a qualified ophthalmologist, optometrist or your general practitioner. Hopefully the information will be of use prior to and following a consultation which it supplements and does not replace.

Copyright

All images and graphics used in this document are subject to copyright law. Mr Tanner is particularly grateful to Mr JJ Kanski and for allowing reproduction of several of his clinical photos on this document.